

Negligible Protection of Pancreas by Topical Curcumin in Streptozotocin Induced Diabetic Wounded Rats

Vinay Kant¹, Dinesh Kumar¹, Vijayta Gupta², and Babu L Jangir³

¹Division of Pharmacology and Toxicology, Indian Veterinary Research Institute, Izatnagar, Bareilly, Uttar Pradesh, India

²Department of Chemistry, University of Jammu, J&K, India

³Division of Pathology, Indian Veterinary Research Institute, Izatnagar, Bareilly, Uttar Pradesh, India

E-mail: drvinaykant2001@yahoo.co.in, drvinaykantluvas@gmail.com

(Received 12 December 2019; Revised 6 January 2020; Accepted 23 January 2020; Available online 31 January 2020)

Abstract - Damage or non-functioning of beta cells of Langerhans islets of pancreas causes Type I diabetes. Curcumin, a bioflavonoid, has shown some tissue regenerative properties. It has shown a very good wound healing action in diabetic animals after topical applications. In view of this, we planned to study the regenerative action of curcumin on damaged pancreas of diabetic rats after its topical applications on wounds. Damage of pancreas and induction of Type I diabetes in rats was achieved by single intraperitoneal injection of streptozotocin (60mg/kg b.wt.). Thereafter, open excisional wounds were created and wounded rats were divided into three groups viz. i) healthy control (non-diabetic), ii) Diabetic control and iii) Diabetic-treated. Pluronic F-127 gel (25%) was applied topically on wounds of group I and II once daily for 19 days. Curcumin (0.3%) in gel was topically applied similarly on group III. Average body weight gain was less and blood glucose levels were high in group II and III. There were also higher levels of MDA in group II and III. Histopathologically, atrophy and loss of intactness of beta cells of Langerhans islets in the pancreas were evident in group II and III, as compared to group I. In conclusion, topical applications of curcumin on wounds of diabetic rats did not able to prevent the damage of beta cells of the pancreas produced by single intraperitoneal injection of streptozotocin (60mg/kg b.wt.). In future, the other higher or lower concentrations of curcumin and their nano-formulations may be tried to evaluate the protective actions.

Keywords: Streptozotocin, Pancreas, Curcumin, Wound.

I. INTRODUCTION

Diabetes mellitus is a very complex disease in people, which is also equally affecting the dog and cat [1]. It is a life-long disease and marked by elevated blood sugar levels. Diabetes and its subsequent complications present a significant challenge to our healthcare system. It is a serious problem of public health worldwide and it tends to increase in numbers. Diabetes is a disease of altered glucose homeostasis and persistent hyperglycemia, which leads to advanced glycation end-products (AGE). This is primarily responsible for the damage of cells having a slow turn over (like neuronal tissue). Type I diabetes is associated with the damage or non functioning of beta cells of Langerhans islets of pancreas. Streptozotocin (STZ) has been commonly used compound to for experimental induction of insulin dependent diabetes mellitus (IDDM) in animals and non-insulin dependent diabetes mellitus

(NIDDM) with hypoinsulinemia in neonates. Induction of experimental diabetes in rats using streptozotocin is very convenient and simple. Clinical symptoms of diabetes are clearly seen in rats within 2-4 days following single intravenous or intraperitoneal injection of 60 mg/kg STZ [2]. Streptozotocin has been widely used to induce type 1 diabetes in animal models especially rats and mice, if administered either intravenously or intraperitoneally [3]. In nude mice, STZ at the dose rate of 150 mg/kg is sufficient to induce pathological levels of blood glucose [4]. Diabetes mellitus has also been induced in rats by a single intraperitoneal injection of STZ at different dose ranges *i.e.* 50 mg/kg to 120 mg/kg [5]. Tropical ulcer, vascular abnormality, poor wound healing etc. are some of the late complications of diabetes manifestation [6]. WHO estimates that by 2025 as many as 200–300 million people worldwide would have developed type 2 diabetes [7]. Impaired wound healing is a common complication of diabetes mellitus [8]. Diabetes is the leading cause of lower extremity amputations and more than a million amputations are performed each year as a consequence to diabetes [9]. Cutaneous diabetic wounds in addition to causing pain and discomfort and predisposing the patient to superficial and chronic infection, involve significant cost associated with the long term treatment.

Curcumin, a bioflavonoid, is a unique antioxidant. This contains a variety of functional groups, including carbon-carbon double bonds, and phenyl rings containing varying amounts of hydroxyl and methoxy substituent [10]. It has shown some promising tissue regenerative properties. It has shown very good wound healing actions in diabetic animals after topical applications as well other route for systemic administration [11-13]. Topical formulation is the most commonly preferred and suited formulation used for applications on the most types of cutaneous wounds. Therefore, in view of this, in present study was planned to study the protective action of curcumin on streptozotocin induced pancreas damage after its topical applications on wound of diabetic rats.

II. MATERIALS AND METHODS

A. Animals

Healthy adult male Wistar rats (170-200 g) were purchased from Laboratory Animal Resource Section,

Indian Veterinary Research Institute, Izatnagar (U.P.), India. The animals were housed in polypropylene cages. They were maintained on a 12:12 h light dark cycle in a climatically controlled room (temperature of $22 \pm 2^\circ\text{C}$) with free access to standard feed and water. Animals were acclimatization for a period of a week before the commencement of trials. A balanced feed procured from Feed Technology Unit of IVRI, Izatnagar was used throughout the period of study. The composition of feed is tabulated below and was fed to rats @ 15 g/rat twice daily. The experimental protocol was approved by the Institute Animal Ethics Committee.

B. Damage of Pancreas by Streptozotocin and Wound Creation

Pancreas was damaged in some rats by single intraperitoneal injection of streptozotocin (60mg/kg b.wt., SRL, India) to induce the diabetes. Fresh injection of streptozotocin was prepared in citrate buffer solution (0.1M, pH 4.5). The fasting blood glucose levels of all rats were determined using glucometer (On Call Plus Blood glucose meter). Rats were monitored for blood glucose levels. The rats showing ≥ 300 mg/dl fasting blood glucose levels after 48 hours of administration of streptozotocin were considered as diabetics. The open excision-type wound 2×2 cm² (≈ 400 mm²) was created on the back of healthy and diabetic animals after 7 days of diabetic induction. The wound creation was done under pentobarbitone sodium (40 mg/kg) anesthesia. Rats were housed individually in properly disinfected cages after recovery from anesthesia.

C. Grouping

Wounded rats were divided equally in the following three groups:

1. Healthy control (Non-diabetic): 400 μl of pluronic F-127 (PF-127) gel (25%) was applied on the wounds once daily for 19 days.
2. Diabetic control: 400 μl of PF-127 gel (25%) was applied on the wounds once daily for 19 days.
3. Diabetic treated: 400 μl of curcumin (0.3%, Sigma Aldrich) in PF-127 gel (25%) was applied topically on wounds once daily for 19 days.

D. Parameters

Body weight and blood glucose of all rats of all the three groups was measured before injection of streptozotocin (Day 0) and after 19 days of treatment of wounds (Day 19).

E. Pancreas Harvesting and Estimation of Different Parameters

Animals were killed after 19 days of treatment of wounds, and pancreas from each animal was collected. One portion of pancreas was homogenized in ice-cold phosphate buffer saline (pH 7.4). The homogenized tissue was centrifuged at

12,000 rpm for 10 min at 4°C . The supernatant was collected and used for the estimation of malondialdehyde (MDA) level for lipid peroxidation as per the method described by Shafiq-Ur-Rehman [14]. The other portion was stored in 10% neutral buffer formalin for histopathological evaluation. These tissues were paraffin embedded and cut into 5 μm thick sections. Thereafter, they were stained with *Hematoxylin and Eosin (H&E)* as per standard procedure. The stained sections were visualized under light microscope at magnification 40x.

F. Statistical Analysis

Results are expressed as mean \pm S.E.M. with n equal to the number of replicates. The statistical significance was analyzed by applying suitable test using the Graph Pad Prism v4.03 software program (San Diego, CA, USA). The differences between the different values were considered statistically significant at $P < 0.05$ or lower.

III. RESULTS AND DISCUSSION

All the animals of this study were closely monitored throughout the experiments. The diabetic rats of this experiment showed loss of body weight (Fig. 1) and elevated blood glucose levels (Fig. 2), polyphagia, polydipsia, polyuria, dull and depressed initially. This revealed that the diabetes was persistent throughout the experiment in streptozotocin injected rats. STZ is an antibiotic isolated from cultures of *Streptomyces achromogenes*. It is composed of the cytotoxic moiety i.e. 1-methyl-1-nitrosourea (MNU) attached to the carbon-2 position of glucose. Streptozotocin injection causes degeneration of the beta cells of Langerhans islets [15]. STZ-induced β cell death is due to alkylation of DNA [16]. DNA damage induces activation of poly ADP-ribosylation, which is likely to be more important for diabetes induction than DNA damage itself [17]. Streptozotocin is adequately similar enough to glucose to be transported into the β cell by the glucose transporter 2 (GLUT2), but is not recognized by the other glucose transporters. This explains its relative toxicity to beta cells, since these cells have relatively greater high levels of GLUT2 [18]. Curcumin has showed wound healing properties in healthy and diabetic rats through several pathways. Several recent studies have shown that curcumin has cytoprotective, antioxidant, anti-inflammatory, antimicrobial, antiparasitic, antimutagen and anticancer properties [19-21]. Curcumin is considered as a classical phenolic chain-breaking antioxidant, which donates H-atoms from its phenolic group [22]. Thus, the phenolic group of curcumin is essential for the free-radical-scavenging activity and presence of methoxy group further increases the activity [23]. Curcumin also possess very good anti-inflammatory potentials, which appears to be mediated through the inhibition of induction of cyclooxygenase-2 (COX-2), lipooxygenase, inducible nitric oxide synthase (iNOS) and production of cytokines such as, interferon- γ and TNF, and activation of transcription factors like nuclear factor kappa B (NF- κ B).

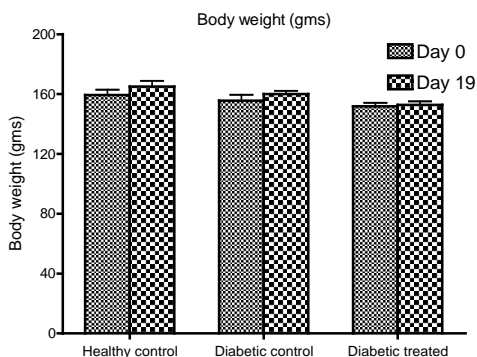


Fig.1 The Average Body Weight (gms) of Different Groups on Different Days. Values are Presented as Mean± SEM, n=5.

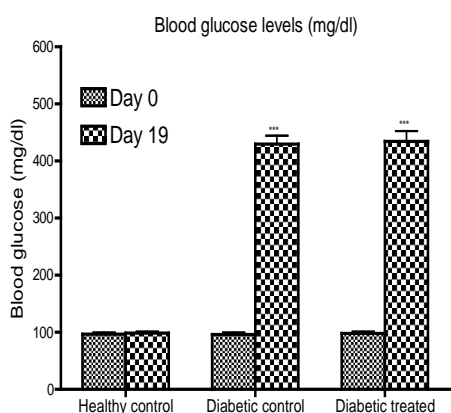


Fig. 2 The Average Blood Glucose Levels (mg/dl) of Different Groups on Different Days.

Values are presented as mean± SEM, n=5. *** $p < 0.001$ indicate significant difference compared with the value of day 0 of same group and activator protein-1 [24]. Curcumin treatments have caused reduction in wound-healing time, improved collagen deposition and increased fibroblast as well as vascular density in wounds [25]. Curcumin enhances expression of TGF-β in both normal and impaired healing wounds [26]. The increased expression of TGF-β by curcumin further induces angiogenesis [27] and controls multiple cellular processes involved in cell proliferation, differentiation, apoptosis and extracellular matrix production [28]. The MDA levels in our present study were significantly higher in diabetic control and treated rats (Fig. 3). Topical applications of curcumin were not able to show its antioxidant effects at pancreas level (Fig. 3). Beta cells in Langerhans islets were intact in healthy control group after observing H & E stained histopathological sections of pancreas (Fig. 4). There was atrophy and loss of intactness of beta cells of Langerhans islets in the pancreas of diabetic control and diabetic treated rats, which revealed the damaging effect of streptozotocin (Fig. 4). So, topical applications curcumin on wounds also failed here to provide

protection to the streptozotocin induced pancreas damage. This failure might be due to its hydrophobic and poor penetration properties, which limits its systemic bioavailability for showing the protective action.

Additionally, the concentration of curcumin may be lower for showing the action. Topical nano-formulations of curcumin may be tried in future to enhance its penetration and bioavailability and protective actions on pancreas may evaluated.

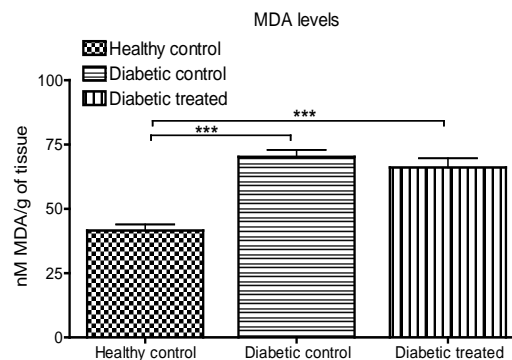


Fig. 3 The Average MDA Levels in Pancreas of Different Groups after 19 Days of Treatment.

Values are presented as mean± SEM, n=5. *** $p < 0.001$ indicate significant difference compared with other group(s).

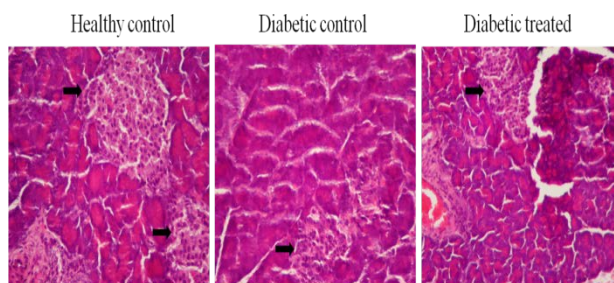


Fig. 4 The H & E Stained Section of Pancreas of Different Groups After 19 Days of Treatment (40X). Black Arrows Indicate the Beta Cells of Langerhans islets of Pancreas

IV. CONCLUSION

On the basis of results of present study, it might be concluded that single intraperitoneal injection of streptozotocin (60mg/kg b.wt.) in rats produced diabetes by producing oxidative stress as well as by damaging the beta cells of the pancreas.

The topical applications of curcumin (0.3%) on the wounds of diabetic rats did not able to prevent as well as reverse this damage of pancreas. In future, the other higher or lower concentrations of curcumin and their nano-formulations may be tried to evaluate the protective actions.

REFERENCES

- [1] M. Hoenig, "Comparative aspects of diabetes mellitus in dogs and cats", *Molecular and Cellular Endocrinology*, Vol. 197, pp. 221–229, 2002.
- [2] D. Elias, H. Prigozin, N. Polak, M. Rapoport, A. W. Lohse, and I. R. Cohen, "Autoimmune diabetes induced by the b-Cell toxin STZ", *Diabetes*, Vol. 43, pp. 992–998, 1994.
- [3] D. Hayashi, K. Kawakami, K. Ito, K. Ishii, H. Tanno, Y. Imai, E. Kanno, R. Maruyama, H. Shimokawa, and M. Tachi, "Low-energy extracorporeal shock wave therapy enhances skin wound healing in diabetic mice: A critical role of endothelial nitric oxide synthase", *Wound Repair and Regeneration*, Vol. 20, pp. 887–895, 2012.
- [4] F. Takeshita, M. Kodama, H. Yamamoto, Y. Ikarashi, S. Ueda, T. Teratani, Y. Yamamoto, T. Tamatani, S. Kanegasaki, T. Ochiya, and G. Quinn, "Streptozotocin-induced partial beta cell depletion in nude mice without hyperglycaemia induces pancreatic morphogenesis in transplanted embryonic stem cells", *Diabetologia*, Vol. 49, pp. 2948–2958, 2006.
- [5] S. Soudamani, T. Malini, and K. Balasubramanian, "Effects of streptozotocin-diabetes and insulin replacement on the epididymis of prepubertal rats: histological and histomorphometric studies", *Endocrine Research*, Vol. 31, pp. 81–98, 2005.
- [6] M. Mishra, H. Kumar, and K. Tripathi, "Diabetic delayed wound healing and the role of silver nanoparticles", *Digest Journal of Nanomaterials and Biostructures*, Vol. 3, pp. 49–54, 2008.
- [7] H. King, R. E. Aubert, and W. H. Herman, "Global burden of diabetes, 1995–2025: prevalence, numerical estimates, and projections", *Diabetes Care*, Vol. 21, pp. 1414–1431, 1998.
- [8] F. W. Logerfo, and J. D. Coffman, "Vascular and microvascular disease of the foot in diabetes. Implications for foot care", *New England Journal of Medicine*, Vol. 311, pp. 1615–1619, 1984.
- [9] V. Shukla, and R. Mani, "Emerging trends in diabetic foot ulcer management in India", *International Journal of Lower Extremity Wounds*, Vol. 9, pp. 111–112, 2010.
- [10] J. S. Wright, "Predicting the antioxidant activity of curcumin and curcuminoids", *Journal of Molecular Structure: THEOCHEM*, Vol. 591, pp. 207–217, 2002.
- [11] G. S. Sidhu, A. K. Singh, D. Thaloor, K. K. Banaudha, G. K. Patnaik, R. C. Srimal, and R. K. Maheshwari, "Enhancement of wound healing by curcumin in animals", *Wound Repair Regeneration*, Vol. 6, pp. 167–177, 1998.
- [12] H. Mani, G. S. Sidhu, R. Kumari, J. P. Gaddipati, P. Seth, and R. K. Maheshwari, "Curcumin differentially regulates TGF-beta1, its receptors and nitric oxide synthase during impaired wound healing", *Biofactors*, Vol. 16, pp. 29–43, 2002.
- [13] G. C. Jagetia, and G. K. Rajanikant, "Acceleration of wound repair by curcumin in the excision wound of mice exposed to different doses of fractionated c radiation", *International Wound Journal*, Vol. 9, pp. 76–92, 2012.
- [14] Shafiq-Ur-Rehman, "Lead-induced regional lipid peroxidation in brain", *Toxicology Letters*, Vol. 21, pp. 333–337, 1984.
- [15] K. Ikebukuro, Y. Adachi, Y. Yamada, S. Fujimoto, Y. Seino, and H. Oyaizu, "Treatment of streptozotocin-induced diabetes mellitus by transplantation of islet cells plus bone marrow cells via portal vein in rats", *Transplantation*, Vol. 73, pp. 512–518, 2002.
- [16] M. Elsner, B. Guldbakke, M. Tiedge, R. Munday, and S. Lenzen, "Relative importance of transport and alkylation for pancreatic beta-cell toxicity of streptozotocin", *Diabetologia*, Vol. 43, pp. 1528–1533, 2000.
- [17] T. Szkudelski, "The mechanism of alloxan and streptozotocin action in B cells of the rat pancreas", *Physiological Research*, Vol. 50, pp. 537–546, 2001.
- [18] Q. Wang, L. A. Muffley, K. Hall, M. Chase, and N. S. Gibran, "Elevated glucose and fatty acid levels impair substance P-induced dermal microvascular endothelial cell migration and proliferation in an agarose gel model system", *Shock*, Vol. 32, pp. 491–497, 2009.
- [19] N. Khanna, "Turmeric -nature's precious gift", *Current Science*, Vol. 76, pp. 1351–1356, 1999.
- [20] G. P. Lim, T. Chu, F. Yang, W. Beech, S. A. Frautschy, and G. M. Cole, "The curry spice curcumin reduces oxidative damage and amyloid pathology in an Alzheimer transgene mouse", *Journal of Neuroscience*, Vol. 21, pp. 8370–8377, 2001.
- [21] B. Kloesch, T. Becker, E. Dietersdorfer, H. Kiener, and G. Steiner, "Anti-inflammatory and apoptotic effects of the polyphenol curcumin on human fibroblast-like synoviocytes", *International Immunopharmacology*, Vol. 15, pp. 400–405, 2013.
- [22] L. R. C. Barclay, M. R. Vinqvist, K. Mukai, H. Goto, Y. Hashimoto, A. Tokunga and H. Uno, "The antioxidant mechanism of curcumin: Classical methods are needed to determine antioxidant mechanism and activity", *Organic Letters*, Vol. 2, pp. 2841–2843, 2000.
- [23] K. I. Priyadarsini, D. K. Maity, G. H. Naik, M. S. Kumar, M. K. Unnikrishnan, J. G. Satav, and H. Mohan, "Role of phenolic O:H and methylene hydrogen on the free 120 Menon and Sudheer radical reaction and antioxidant activity of curcumin", *Free Radical Biology and Medicine*, Vol. 35, pp. 475–484, 2003.
- [24] V. P. Menon, and A. R. Sudheer, "Antioxidant and anti-inflammatory properties of curcumin", *Advances in Experimental Medicine and Biology*, Vol. 595, pp. 105–125, 2007.
- [25] R. L. Thangapazham, A. Sharma, and R. K. Maheshwari, "Beneficial role of curcumin in skin diseases", *Advances in Experimental Medicine and Biology*, Vol. 595, pp. 343–357, 2007.
- [26] H. Mani, G. S. Sidhu, R. Kumari, J. P. Gaddipati, P. Seth, and R. K. Maheshwari, "Curcumin differentially regulates TGF-beta1, its receptors and nitric oxide synthase during impaired wound healing", *Biofactors*, Vol. 16, pp. 29–43, 2002.
- [27] G., Ferrari, B. D., Cook, V. Terushkin, G. Pintucci, and P. Mignatti, "Transforming growth factor-beta 1 (TGF-beta1) induces angiogenesis through vascular endothelial growth factor (VEGF)-mediated apoptosis", *Journal of Cellular Physiology*, Vol. 219, pp. 449–458, 2009.
- [28] A. Agrotis, N. Kalinina, and A. Bobik, "Transforming growth factor-beta, cell signaling and cardiovascular disorders", *Current Vascular Pharmacology*, Vol. 3, pp. 55–61, 2005.